

A Less-Invasive Protocol for EVAR

Can lower-profile endografts improve the safety and efficiency of EVAR?

BY ZVONIMIR KRAJCER, MD

Despite the well-accepted safety and effectiveness of endovascular aneurysm repair (EVAR) for the treatment of abdominal aortic aneurysm (AAA), the prevention of access-related morbidity continues to pose a significant challenge. Traditional bilateral femoral artery cutdown and surgical closure increases groin complication risks, especially in patients with small-caliber, severely calcified, or tortuous access vessels.¹ Although first-generation EVAR devices were 22- to 27-F outer diameter (OD) in profile, newer-generation endografts incorporate even lower-profile delivery systems that, in some cases, enable totally percutaneous EVAR (PEVAR).

PEVAR was first tried at our institution in 1998, and results were reported in 1999.² In early single-center PEVAR reports, the success rates varied significantly and were less than optimal. The question remained, will the smaller-profile devices lead to improved PEVAR results? More recently, single-center publications revealed that as the EVAR device profile decreased and the experience increased, the success rate has increased to 96%.³ Starnes et al reported that the success rate for patients treated with a sheath size > 20 F was 78% compared to 98.4% for patients treated with a sheath size ≤ 18 F.³ In another meta-analysis, Georgiadis et al reported that the risk of conversion to cutdown during PEVAR increased by 78% with sheath sizes that were 20 F or greater.⁴ Of the endografts that are commercially available today, the Ovation Prime™ abdominal stent graft (TriVascular, Inc., Santa Rosa, CA) offers the lowest delivery system profile (14-F OD) and should be ideally suited for PEVAR (Figure 1).

THE ADVANTAGES OF PEVAR

Although single-center PEVAR reports have shown significant potential benefits to patients, physicians, and hospitals, the access-related complications (such as excessive procedural blood loss) still remain as a concern for certain patients. Several factors, including body mass index, operator experience, and femoral artery calcification, are known to influence success rates; however, the most consistent predictor of technical success is sheath diameter.^{3,4} Recent studies have confirmed that smaller

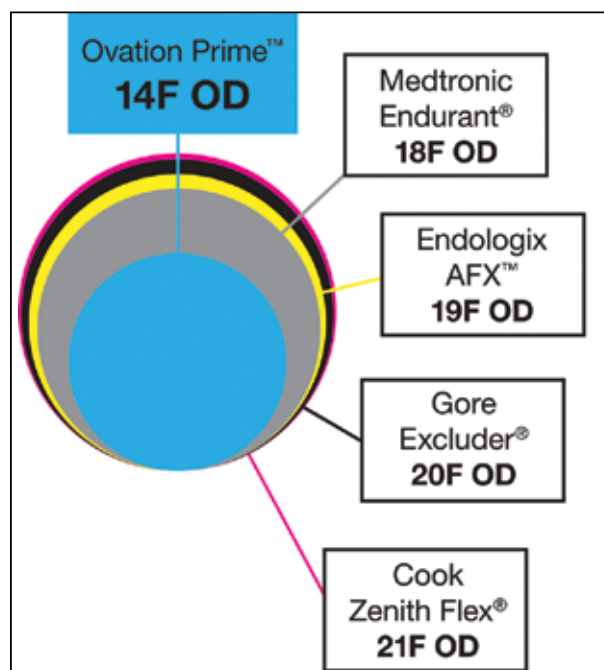


Figure 1. Outside sheath and/or device diameter of the Ovation Prime graft and other currently commercially available endografts in the United States. Note that the lowest-profile device is the Ovation Prime endograft.

sheath diameters are associated with higher technical success rates and a lower risk of conversion to surgical cutdown.³⁻⁵ Based on these findings, the 14-F Ovation Prime stent graft might be better suited for PEVAR compared to other stent grafts that have delivery system profiles ranging from 18 to 21 F.

One of the often-overlooked advantages is the use of local anesthesia during PEVAR. This affords numerous potential advantages to the patient and the physician alike. From the patient's perspective, PEVAR results in less post-operative discomfort, lowers the groin morbidity risk, allows treatment of challenging access anatomy, and enables treatment of those with significant comorbidities who are not suitable candidates for general anesthesia. From the physicians' and payors' perspectives, patient care is deliv-

TABLE 1. RESULTS OF THE OVATION™ PIVOTAL TRIAL

	Femoral Cutdown	Percutaneous Access
Major adverse events at 30 d	3.3% (3/92)	1.4% (1/69)
Treatment success at 1 y	98.9% (91/92)	100% (69/69)
Anesthesia time (mean)	191 min	149 min
Procedure time (mean)	118 min	98 min
Hospitalization time (median)	2 d	1 d

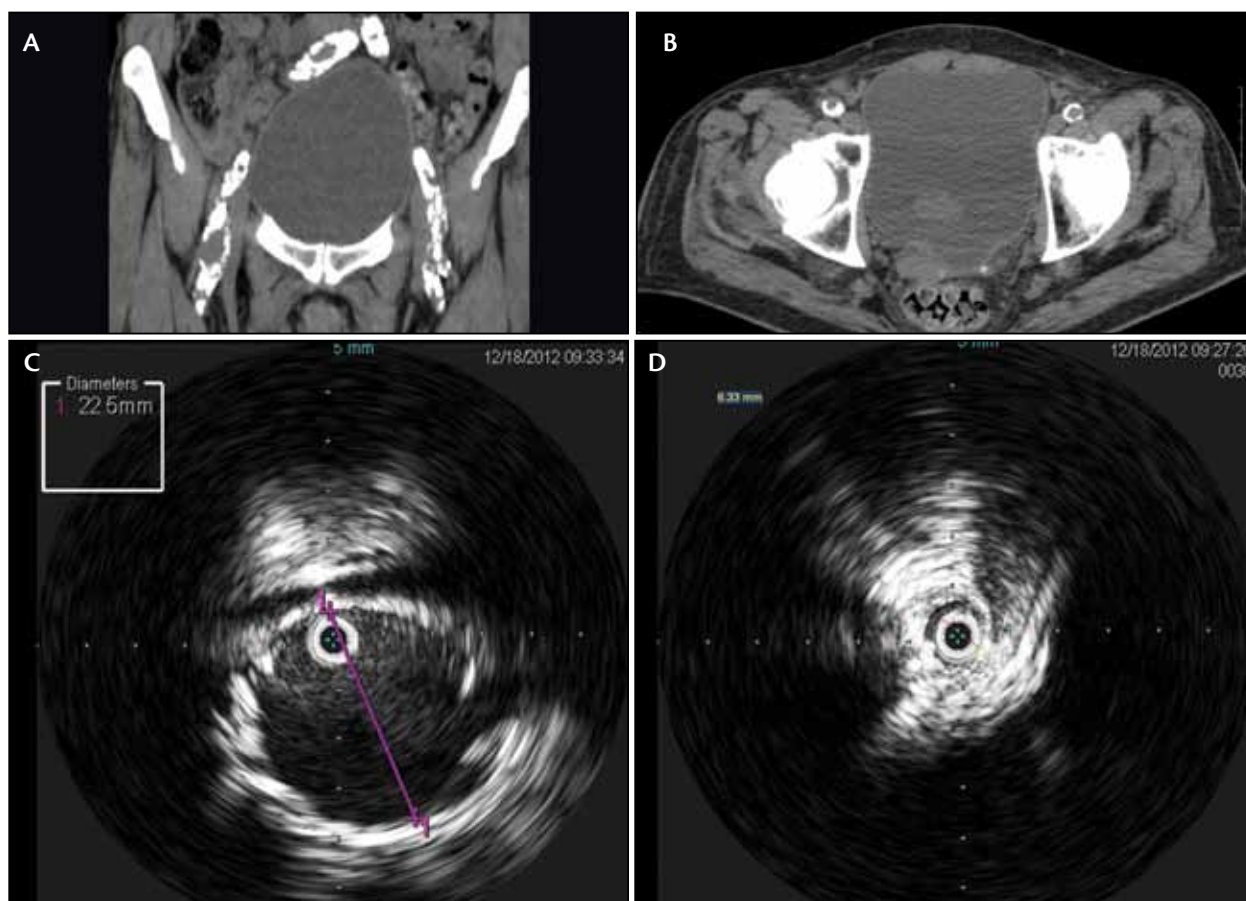


Figure 2. The maximum image projection CT of the femoral and iliac arteries reveals severe calcifications (A). A CT slice image at the access sites reveals circumferential calcification of the left common femoral artery and near-circumferential calcification of the right common femoral artery (B). The intravascular ultrasound image reveals the infrarenal aortic neck diameter to be 22.5 mm (C). The intravascular ultrasound image reveals circumferential calcification of the left common iliac artery that measured 6.3 mm in maximal diameter (D).

ered more cost effectively because general anesthesia is not required, procedure and operating room times are shorter, and hospital stays are also shorter. With the recent emphasis on reducing health care costs without sacrificing patient outcomes, the adoption of PEVAR with the Ovation Prime endograft has great potential to safely expand the eligible EVAR population with less patient morbidity and expense (Figure 1).

CLINICAL DATA ON PEVAR WITH THE OVATION DEVICE

Of course, rigorous evaluation in clinical trials is required to confirm the potential benefits and risks of each particular endograft. The recent Ovation global clinical study provides compelling evidence for the benefits of less-invasive PEVAR protocols using an ultra-low-profile delivery system. This clinical trial enrolled 161 patients with AAA; 69 underwent

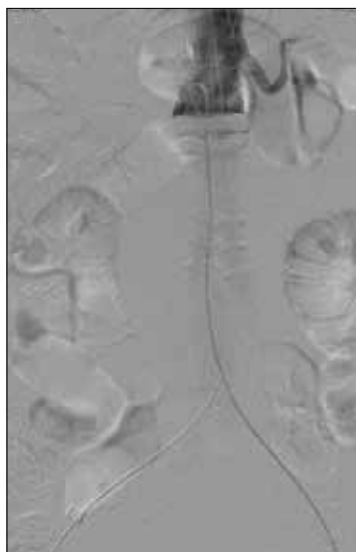

Figure 3. Completion angiographic image obtained with 5 mL of contrast reveals satisfactory positioning of the Ovation Prime endograft and no evidence of endoleak.

results seen with the 19-F OD AFX™ device (Endologix, Inc., Irvine, CA) in the Endologix PEVAR study.⁵

CASE EXAMPLE

Our experience using the Ovation Prime stent graft confirms the benefits observed in recent series. The following is a representative case that exemplifies the benefits of this device. An 87-year-old man with a rapidly enlarging AAA and comorbid conditions (coronary artery disease, angina, chronic obstructive pulmonary disease, intermittent claudication, and chronic renal failure) was referred for EVAR. We decided to perform PEVAR with the Ovation Prime stent graft in order to avoid complications with general anesthesia. The patient's right and left iliac arteries were severely calcified and showed significant narrowing, but his access sites were deemed to be appropriate for percutaneous access (Figure 2).

The procedure was performed under local anesthesia and conscious sedation, and we employed the PEVAR technique using the ProGlide® suture-mediated closure system (Abbott Vascular, Santa Clara, CA) for right and left femoral artery repair. Because of the patient's renal functional impairment, the procedure was performed with intravascular ultrasound guidance (Visions® PV .035 digital IVUS catheter, Volcano Corporation, San Diego, CA), and no contrast was used until completion angiography was performed (Figure 3). There were no complications, and completion angiography demonstrated complete exclusion of the AAA. The patient was discharged 24 hours later. Noncontrast CT at 1-month follow-up demonstrated AAA shrinkage with no reported complications (Figure 4). Notably, this patient

PEVAR, and 92 had traditional femoral cutdown. The access method was left to the discretion of the investigators. Short-term outcomes in PEVAR-treated patients showed some benefit when compared to those treated with cutdown, including greater treatment success; shorter anesthesia, procedure, and hospitalization times; and lower major adverse event rates through 30 days (Table 1).⁶

Outcomes with PEVAR using the Ovation device confirm the encouraging

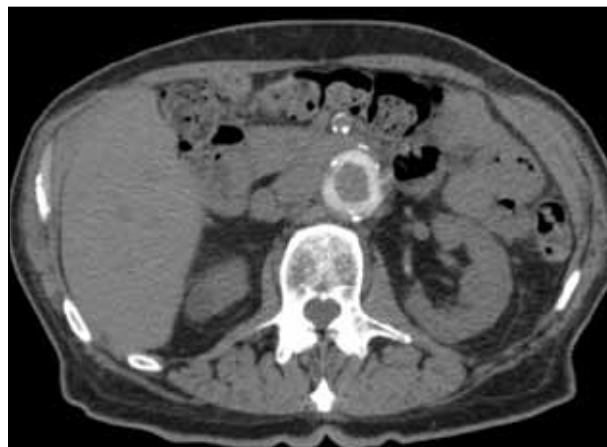


Figure 4. A noncontrast CT image reveals the Ovation Prime seal ring in the infrarenal neck at 1-month follow-up.

was considered high risk for EVAR due to access vessel anatomy and multiple comorbidities.

ENABLING LESS-INVASIVE EVAR PROTOCOLS

Minimally invasive EVAR protocols, including PEVAR under local anesthesia, are appealing to hospitals, patients, and physicians. In the United States in particular, a variety of factors are likely to accelerate the adoption of less-invasive EVAR protocols, including: (1) the increased focus on the cost of health care delivery, (2) increased patient awareness of and preference for treatment options that reduce recovery times, and (3) the availability of lower-profile devices, such as the 14-F OD Ovation Prime abdominal stent graft. The convergence of these factors is likely to create an environment that rewards hospitals and physicians that are equipped to adopt less-invasive and less-expensive AAA treatment modalities that reduce anesthesia use and length of stay.

Evidence to date with the Ovation Prime stent graft suggests that these treatment modalities are feasible and safe in well-selected patients. ■

Zvonimir Krajcer, MD, is Director, Peripheral Intervention, St. Luke's Episcopal Hospital Texas Heart Institute in Houston, Texas. He has disclosed that he is on the speakers' bureau for Medtronic, Endologix, TriVascular, Gore, Bard, Abbott, Volcano, and Bayer. Dr. Krajcer may be reached at (713) 790-9401; zvonkomd@aol.com.

1. Haulon S, Hassen Khodja R, et al. A systematic literature review of the efficacy and safety of the Prostar XL device for the closure of large femoral arterial access sites in patients undergoing percutaneous endovascular aortic procedures. *Eur J Vasc Endovasc Surg.* 2011;41:201-213.
2. Clay P, Krajcer Z, Diethrich EB. Closure of large percutaneous access sites using the Prostar XL percutaneous vascular surgery device. *J Endovasc Ther.* 1999;6:169-170.
3. Starnes BW, Andersen CA, Ronsaville JA, et al. Totally percutaneous aortic aneurysm repair: experience and prudence. *J Vasc Surg.* 2006;43:270-276.
4. Georgiadis GS, Antoniou GA, Papaioakim M, et al. A meta-analysis of outcome after percutaneous endovascular aortic aneurysm repair using different size sheaths or endograft delivery systems. *J Endovasc Ther.* 2011;18:445-459.
5. Krajcer Z, Nelson PR, Bianchi C, et al. Percutaneous endovascular abdominal aortic aneurysm repair: methods and initial outcomes from the first prospective, multicenter trial. *J Cardiovasc Surg.* 2011;52:651-659.
6. Mehta M, Valdes FE, Nolte T, et al. One-year outcomes from an international study of the Ovation abdominal stent graft system for endovascular aneurysm repair. *J Vasc Surg.* In press.